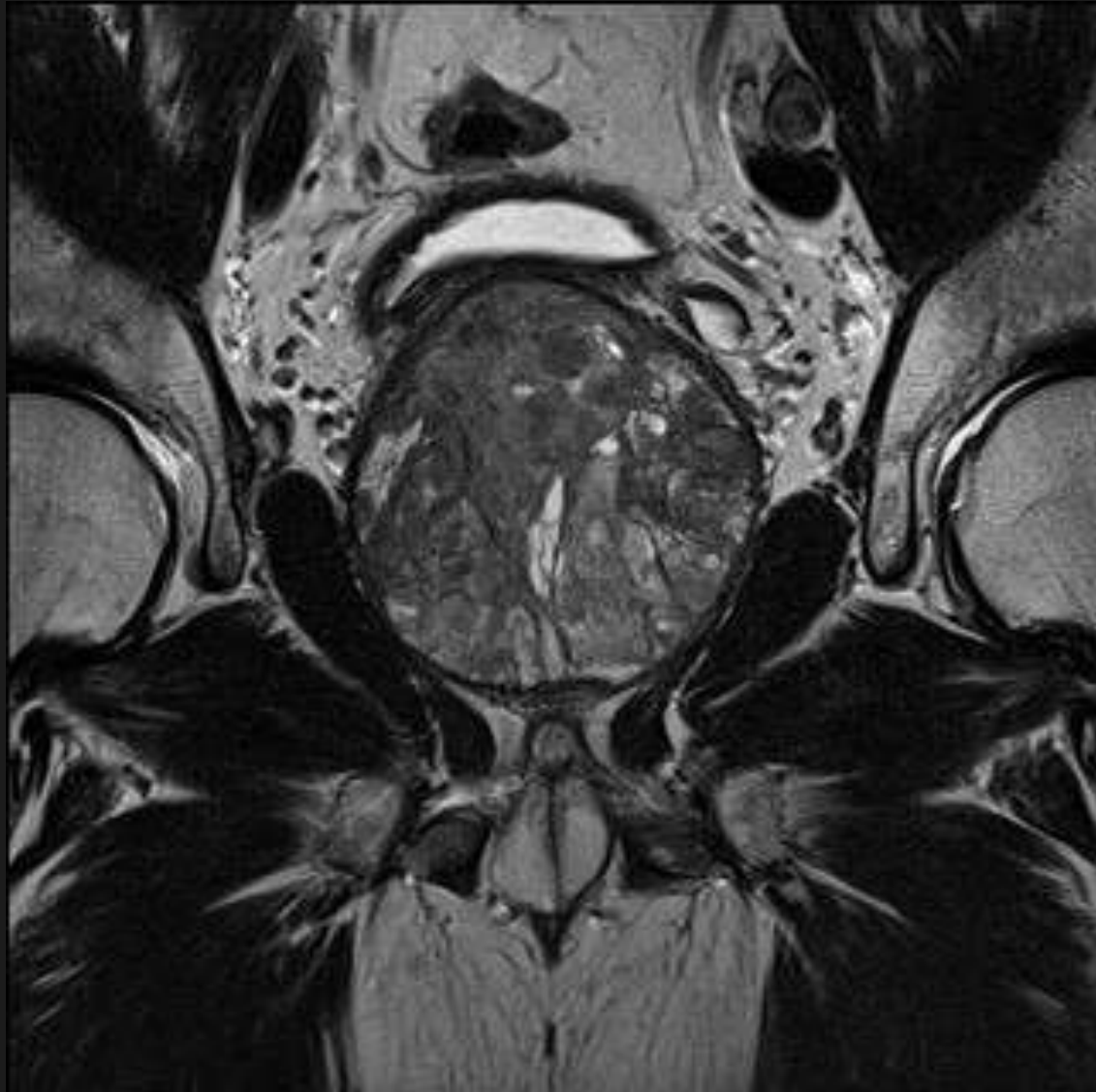

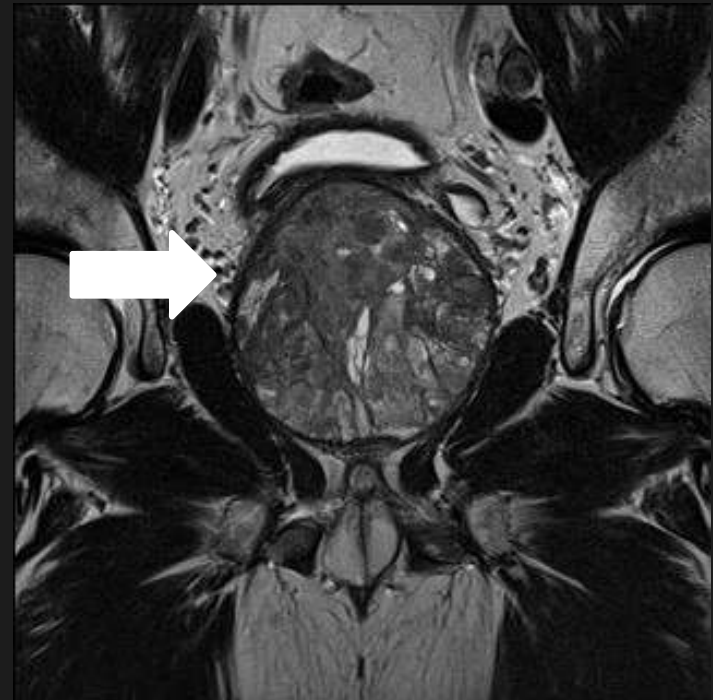Thyroid cancer : facts and figures : an overview.

Rhodri M Evans



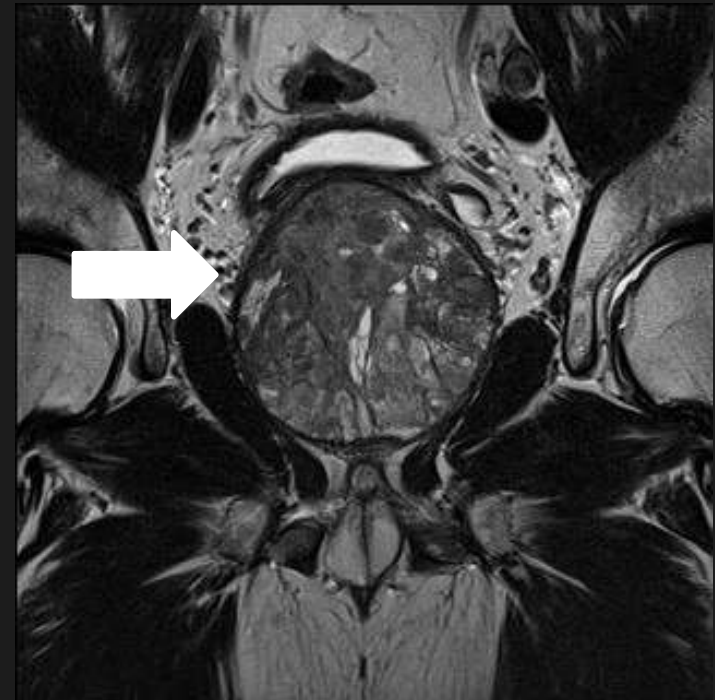Questions?

- Are you in the right room?
- What organ is it?
- Why?



Answers?

- Correct room/session : thyroid
- Prostate
- Analogy
- Occult Ca. prostate :30%
- Occult Ca. thyroid :30%
- Diagnosis?
- “Overdiagnosis”

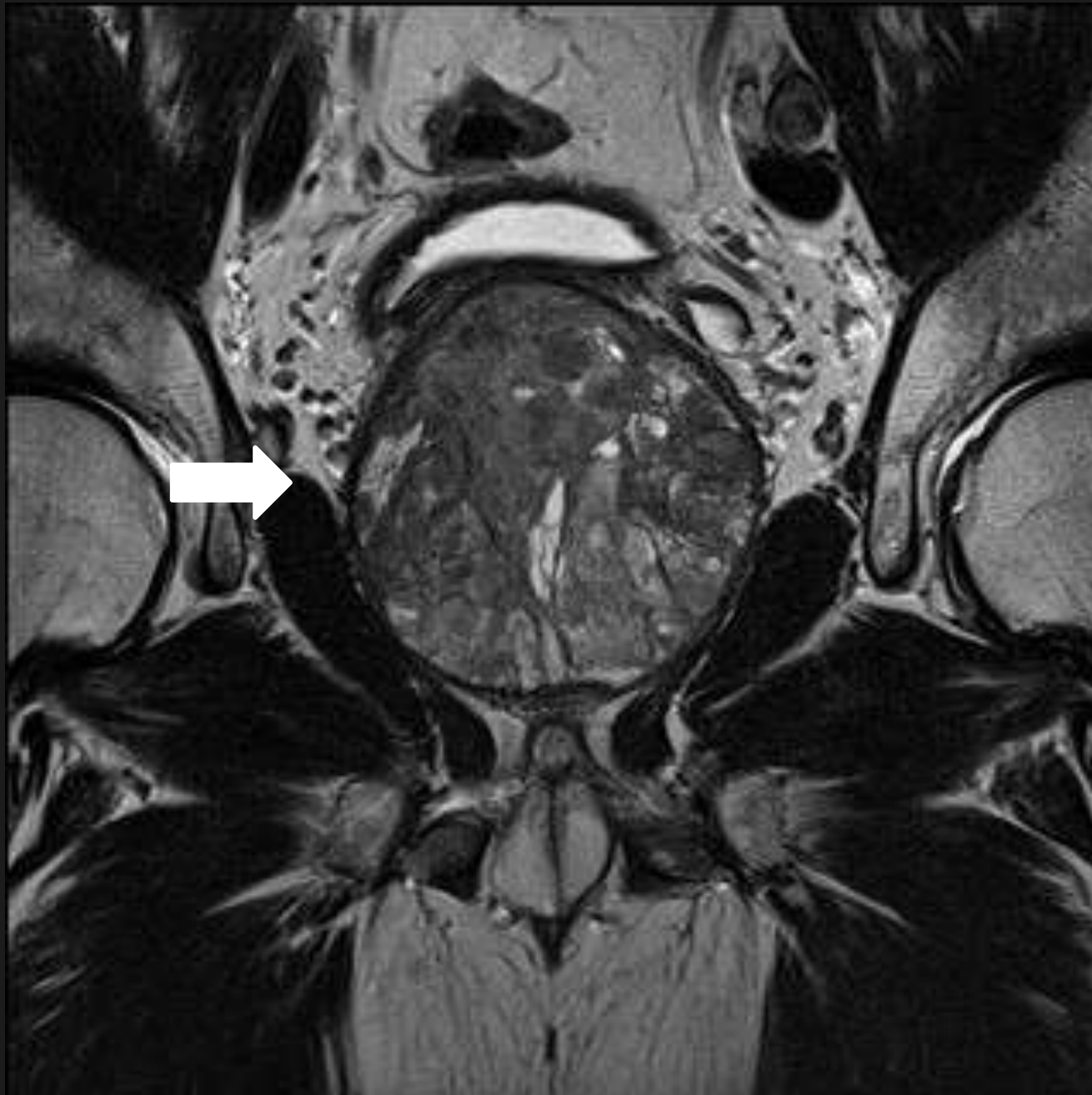


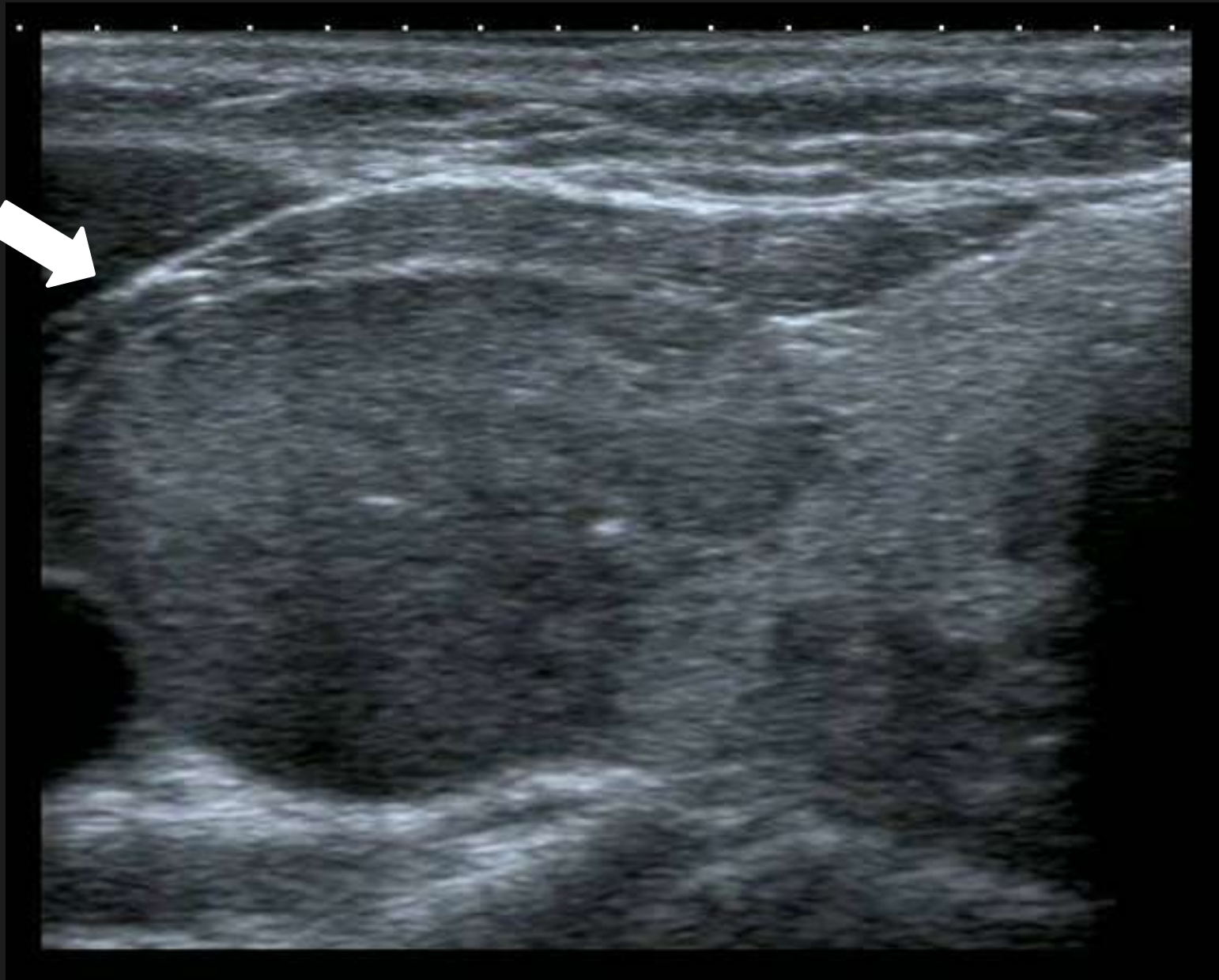Thyroid cancer : zealous imaging has increased detection and treatment of low risk tumours.

Brito,Morris,Montori:BMJ:347,4706.2013

Thyroid cancer : zealous imaging has increased detection and treatment of low risk tumours.

- Zealous : filled with or inspired by intense enthusiasm or zeal
- Overdiagnosis : occurs when people without symptoms are diagnosed with a disease that ultimately will not cause them to experience symptoms or early death





Papillary carcinoma

- 85% of thyroid carcinoma
- Incidence has tripled in last 30 years (USA)
- 3.6/100,000 (1973) to 11.6/100,000 in 2009
- Small (<2cm) account for 90%
- Ultrasound has increased by 80% in last 20yrs
- Use of CT tripled between 1995 and 2005
- 16% of CT/MRI showed incidental thyroid nodules

Papillary carcinoma

- 2.4 increase in reported incidence of thyroid nodules in past three decades (USA)
- Three fold increase in number of biopsies between 1995 and 2005
- Incidence is higher in people with higher socio-economic status
- For each 5% rise of population covered by health insurance – incidence increases by 1.4/100,000 in 25 year period (Wisconsin)

Papillary carcinoma.

- 99% of patients with < 2cm tumours are alive at 20 years
- Autopsy series – large subclinical reservoir
- Thyroidectomies: 60% increase last decade (USA)
- Radio-iodine Rx : 1 in 300 pts in 1973 to 2 in 5 pts in 2006 (USA)
- 15,000 pt. cohort :13% increase in risk of salivary malignancies & 5.7 fold increase in leukaemia

From: Increasing Incidence of Thyroid Cancer in the United States, 1973-2002

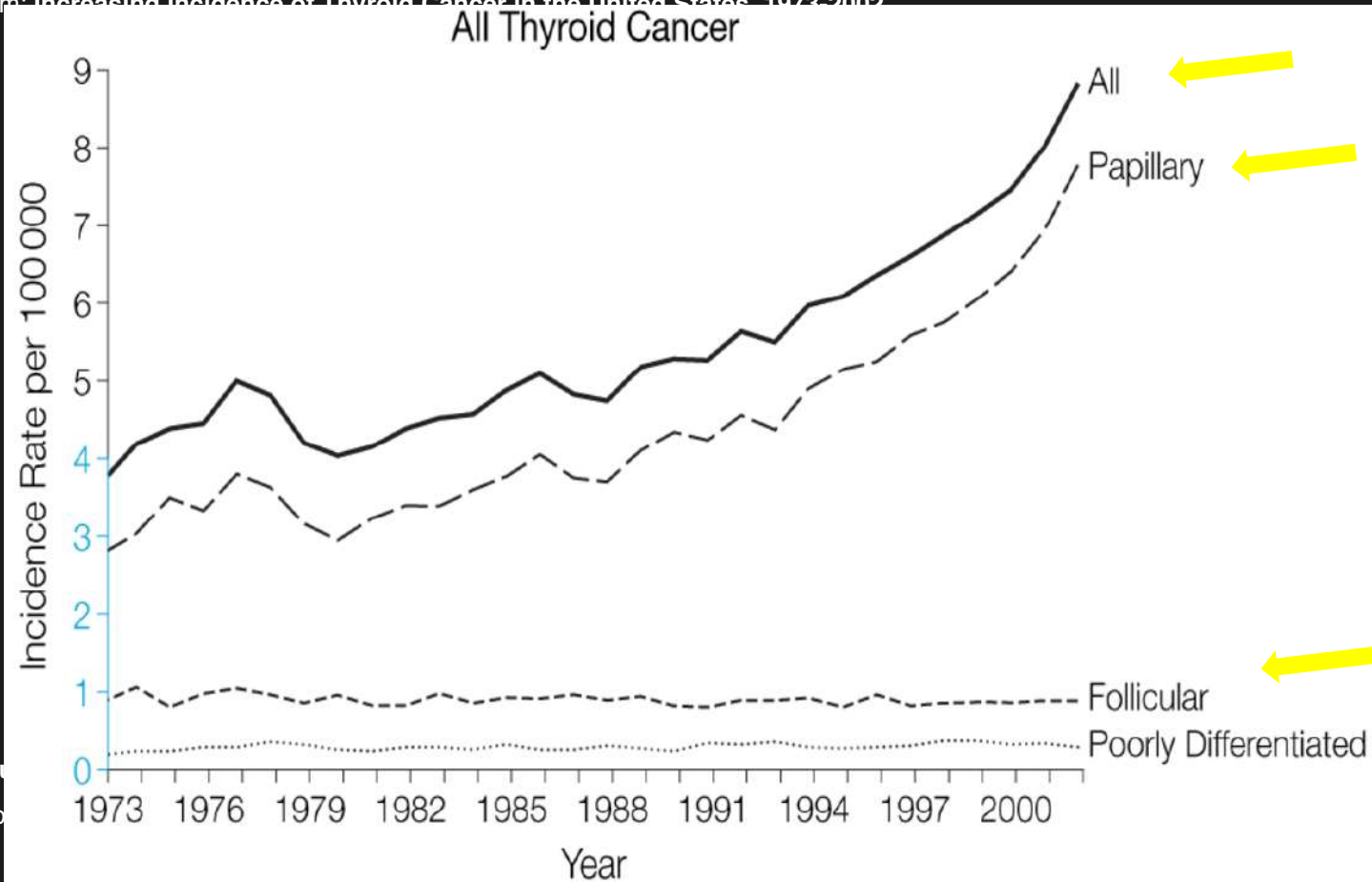


Fig
Pod

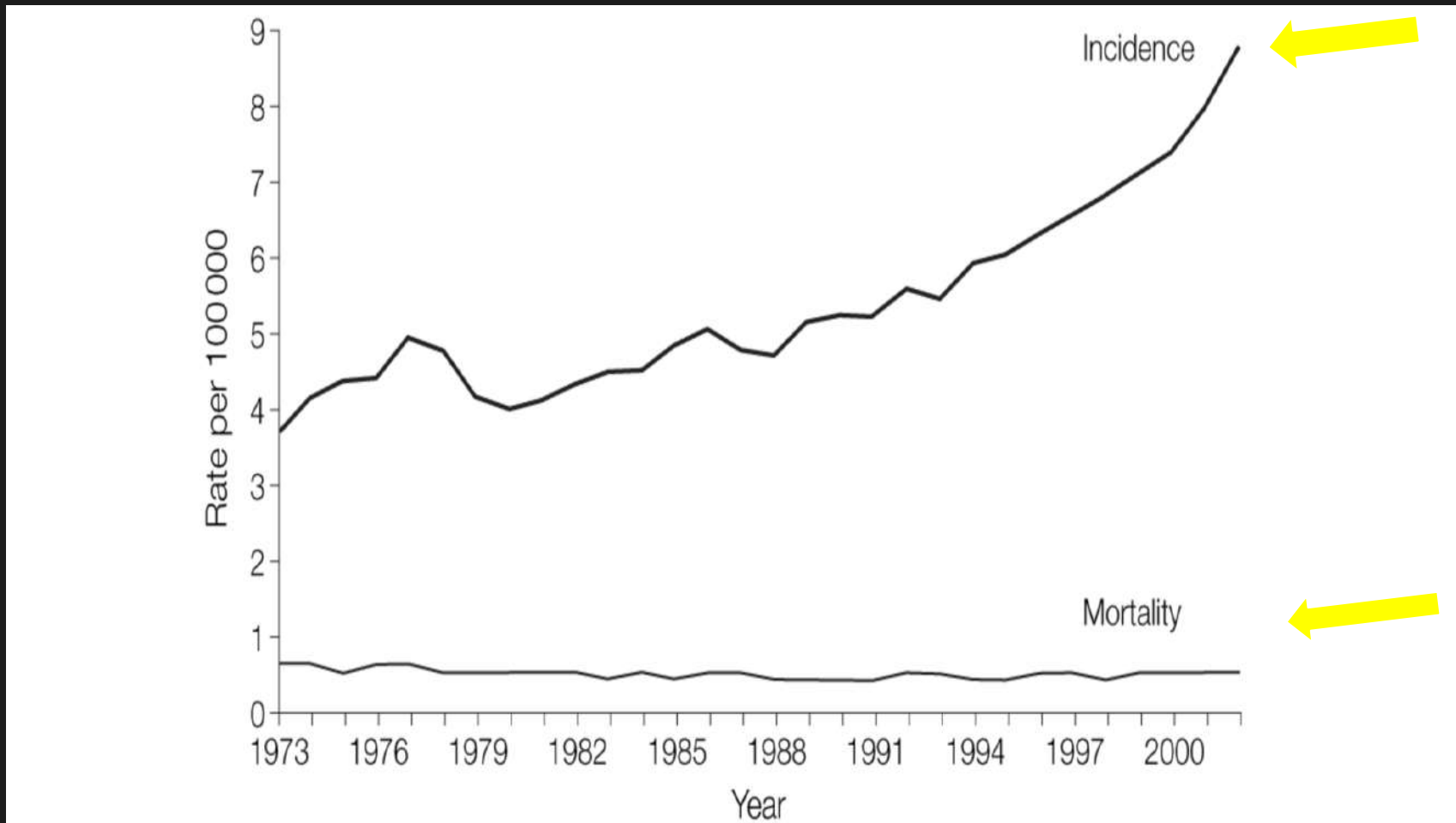
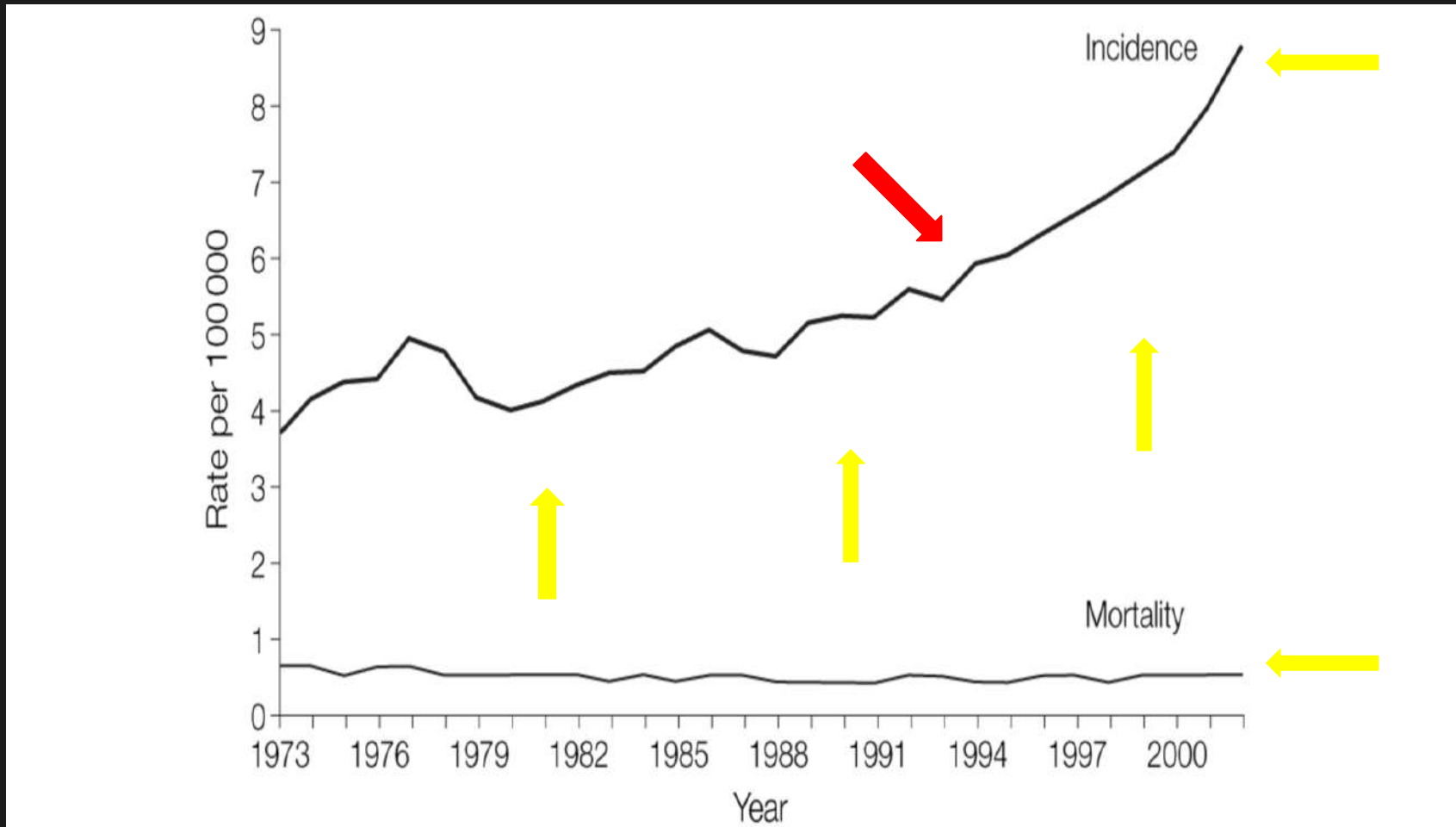


Figure Legend:

From: Increasing Incidence of Thyroid Cancer in the United States, 1973-2002

CT & MRI

Overdiagnosis?

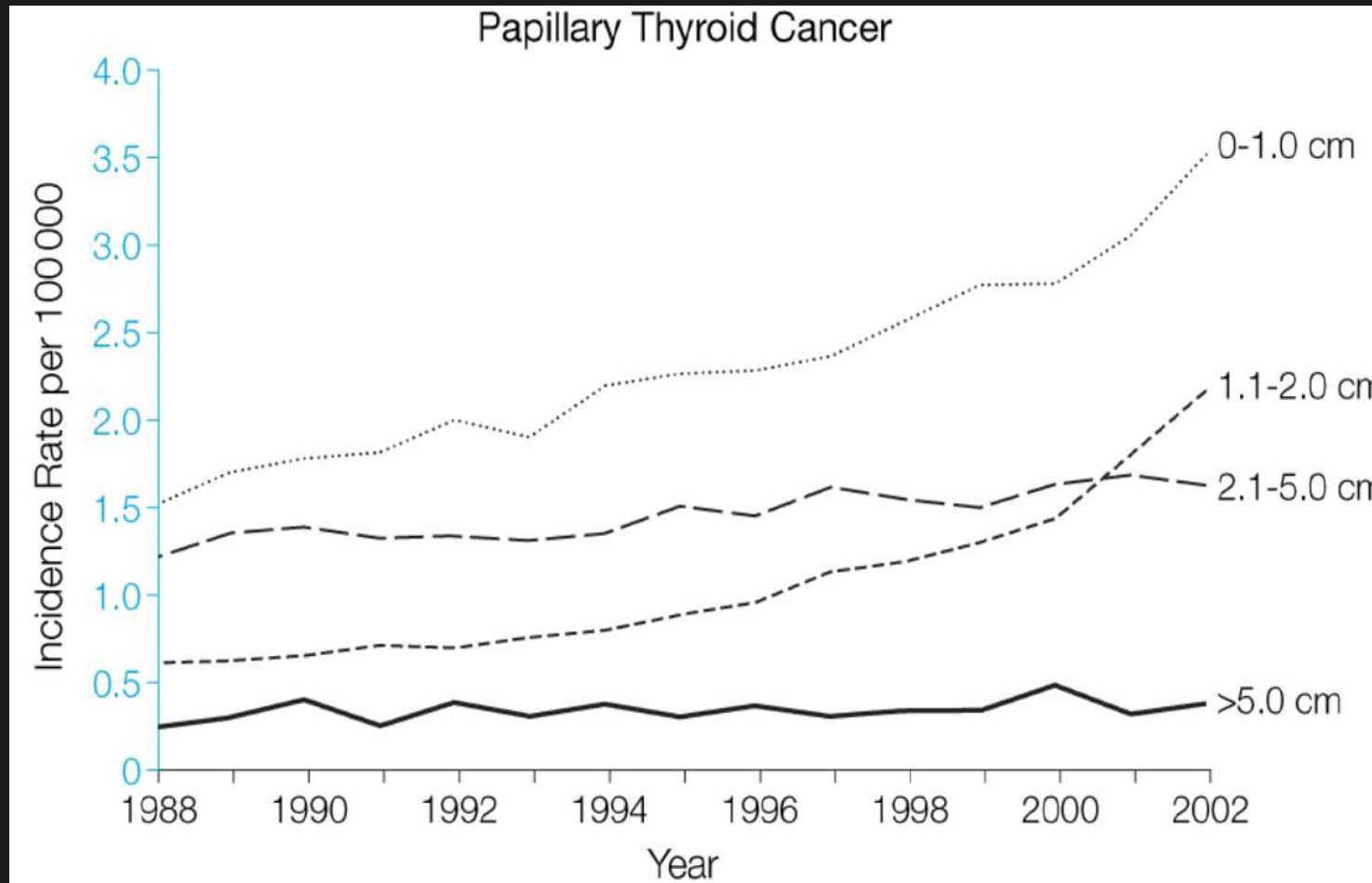


US

FNA

US FNA

Overdiagnosis



From: Increasing Incidence of Thyroid Cancer in the United States, 1973-2002

Overdiagnosis

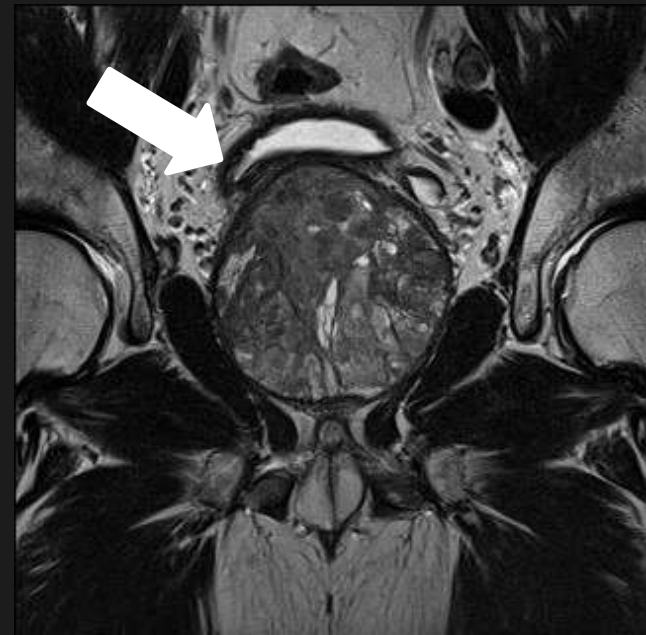
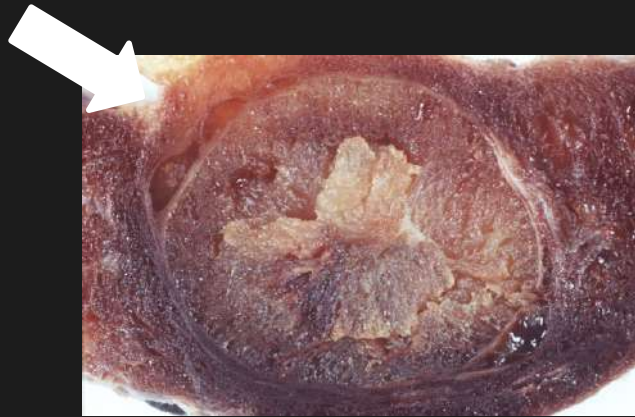
- Responding to the challenge of Overdiagnosis.
- Editorial :Acad.Radiol. 2015.22 : 945-946.
- Overdiagnosed :making people sick in the pursuit of health
- Text (2012),co authors Schwartz & Woloshin

H.Gilbert Welch

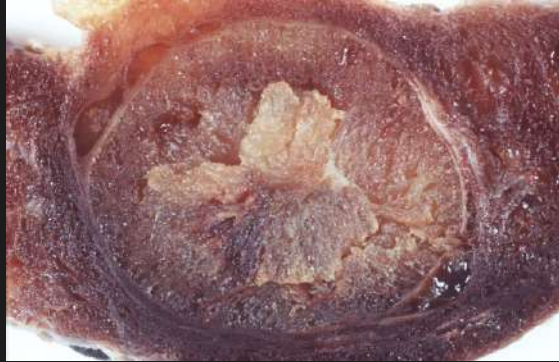
Overdiagnosis



- Earlier and increased numbers of diagnoses
- More diagnosis : more treatment : better health.
- Overdiagnosis : individuals are diagnosed with conditions that will never cause symptoms or death
- More diagnosis : excessive treatment
- If treatment is worse than the disease : harm the patient



Diagnosis :signs ?







Diagnosis :signs ?





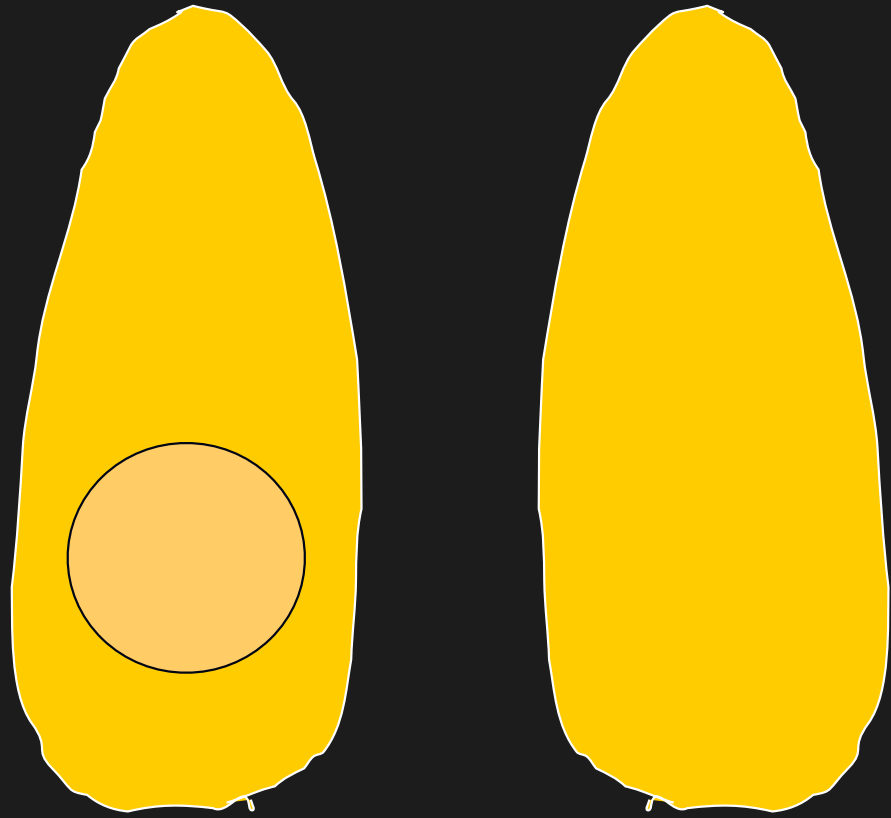


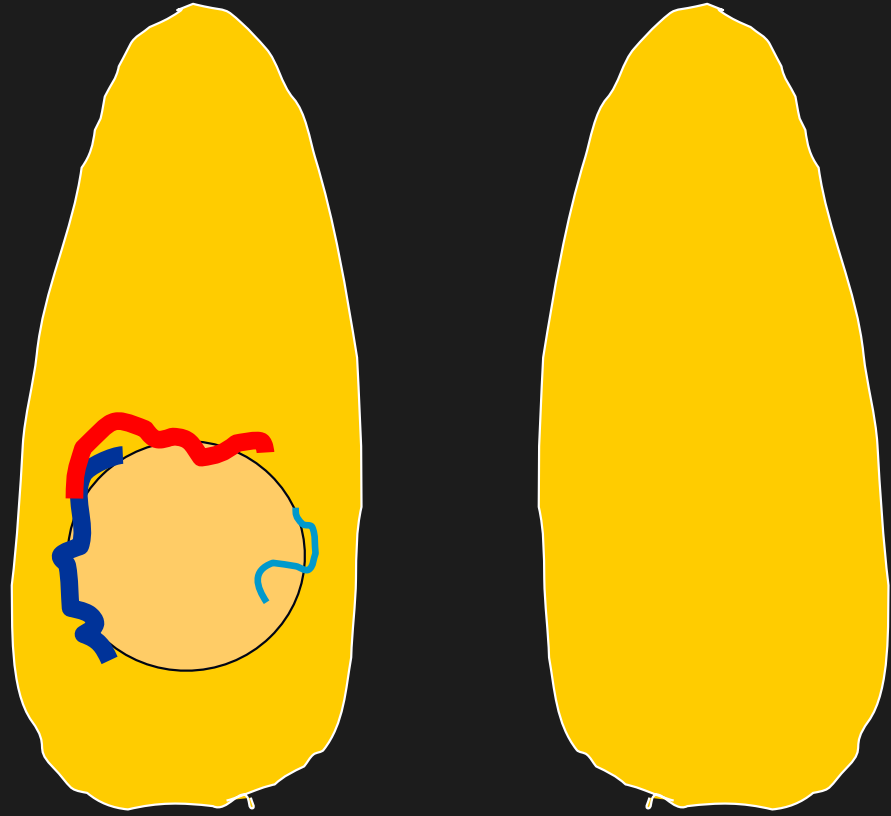















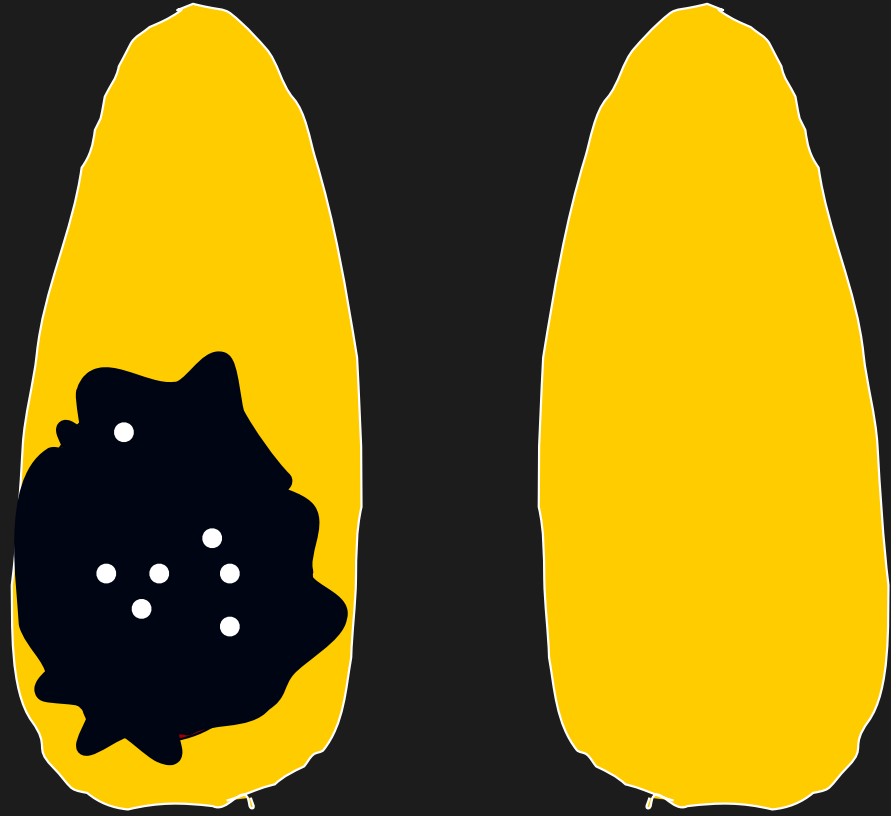













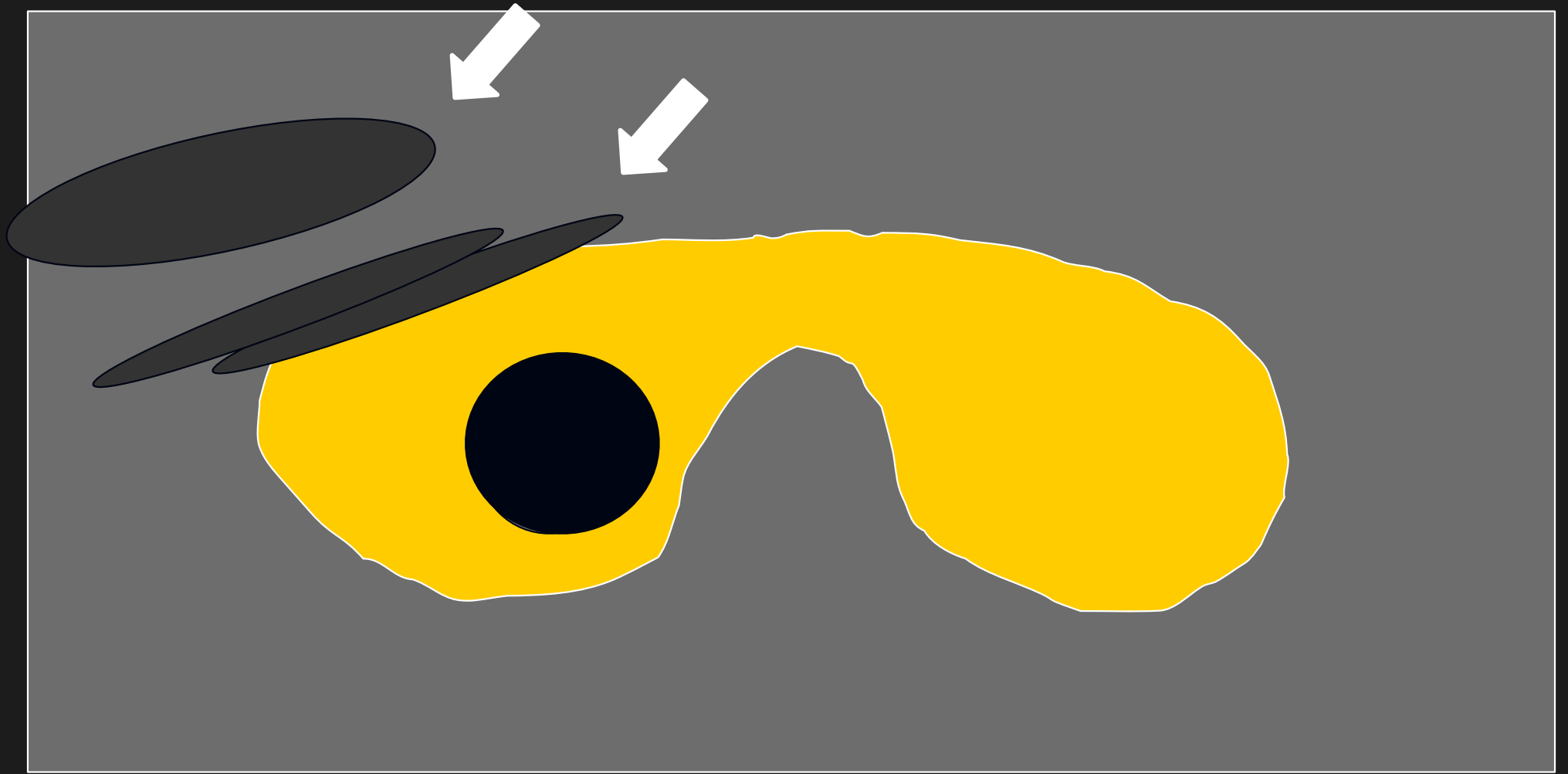






Current evidence?

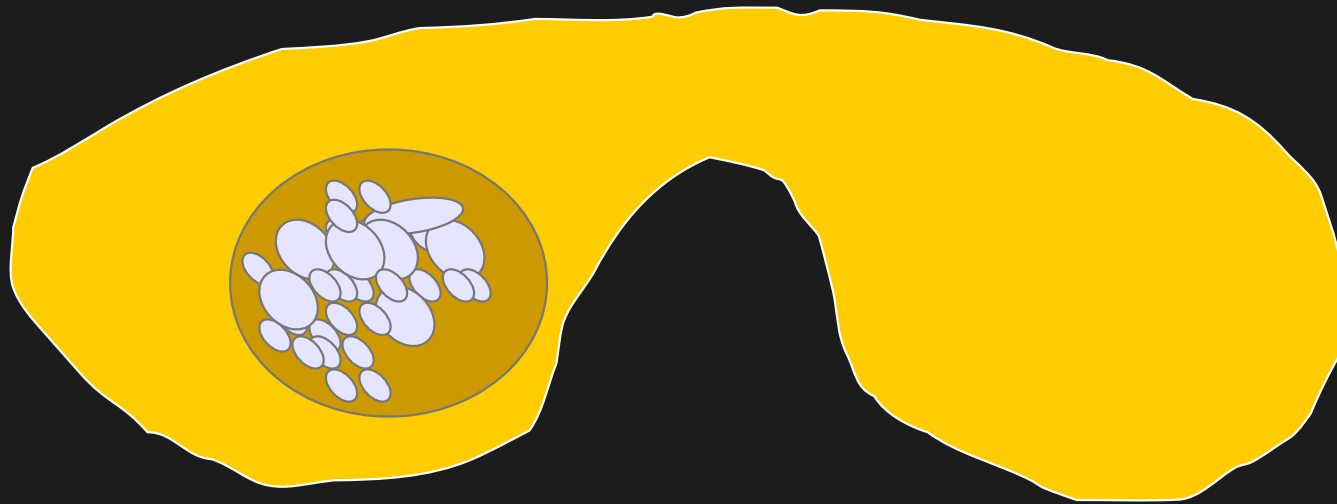
- Moon et al ,2008
- Multicentre retrospective study.
- Definition hypo- echoic
- Spongiform sign
- Taller than wide – shape
- Definition micro-calcification



Spongiform appearance




Spongiform appearance




Spongiform :microcystic components $>50\%$ nodule volume – Benign.

Taller than wide sign – shape of nodule



Not in long axis


Taller than wide sign – shape of nodule



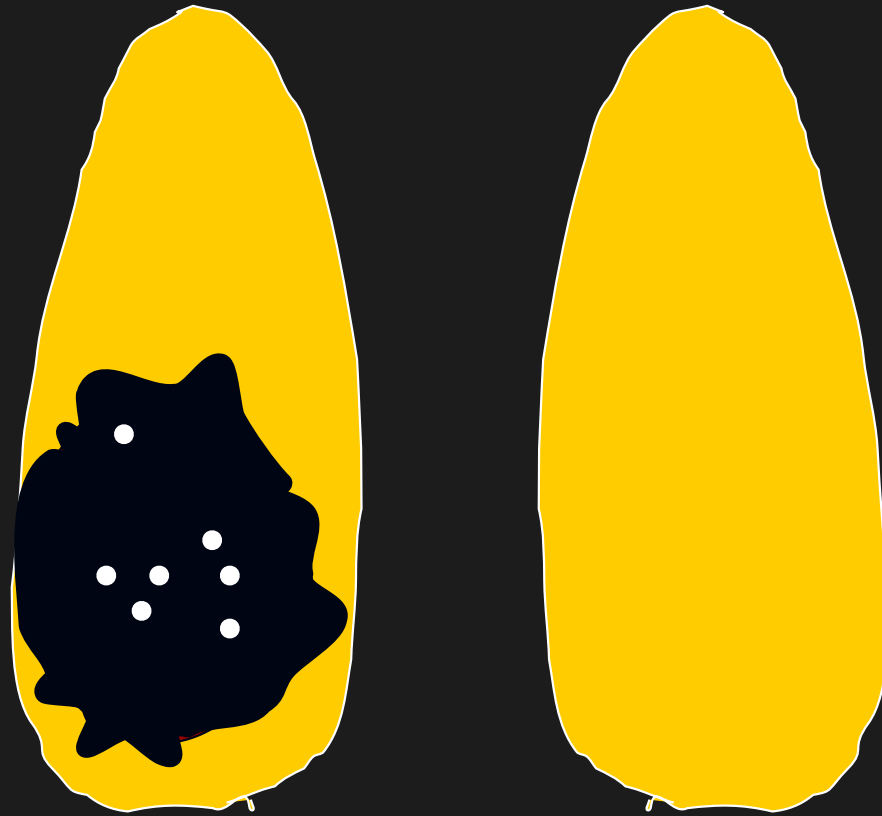
$a/b > 1$: malignant .

$a/b < 1$:benign (Kim)

Taller than wide sign – shape of nodule

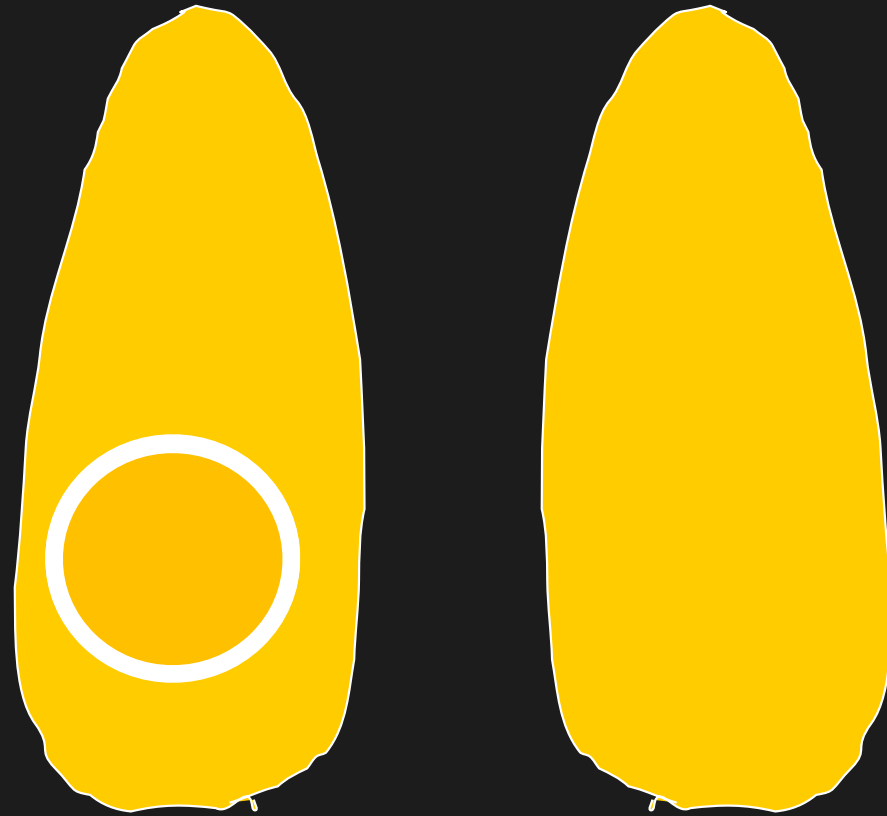


Micro-calcification







1 – 2mm ,may or may not shadow

Eggshell calcification



Byung et al, Ultrasound 2008





Guidelines?

- Kim : nodule should have one of hypoechogenicity,irregular margins,microcalcification,length>width.
- High sensitivity

- Am Assn Clin Endocrin : hypoechoic with one additional feature – irregular margins,length>width or microcalcification
- High specificity

Guidelines?

- Soc.Rad in US :
- >1cm if microcalcification present
- >1.5cm if solid or macro-calcification present
- >2cm if mixed solid/cystic (or mural component in cyst)
- Growth since previous US (interpreted as >3mm)
- Least accurate

Thyroid nodules.

- Radiological Classification.
- Ultrasound classification (U)
- Cytological classification(1 -5)
- Clinical scenario.
- Correctly manage patient.

Nodules – Ultrasound classification

U

1 : Normal.

2 : Benign.

3 : Indeterminate/equivocal.

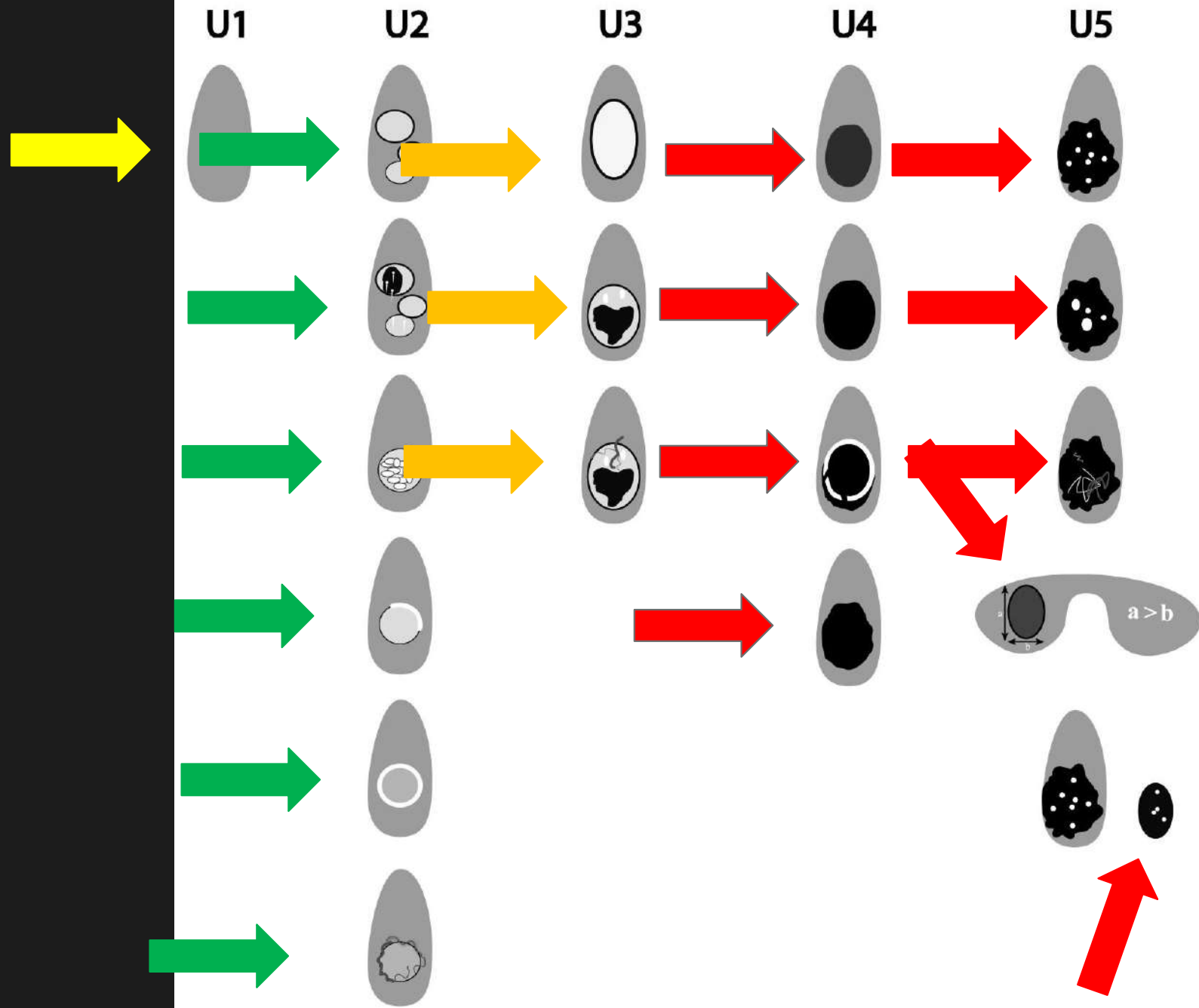
4 : Suspicious.

5 : Malignant



BTA (2014)

Thyroid nodules – Ultrasound(U) classification



Thyroid nodules.

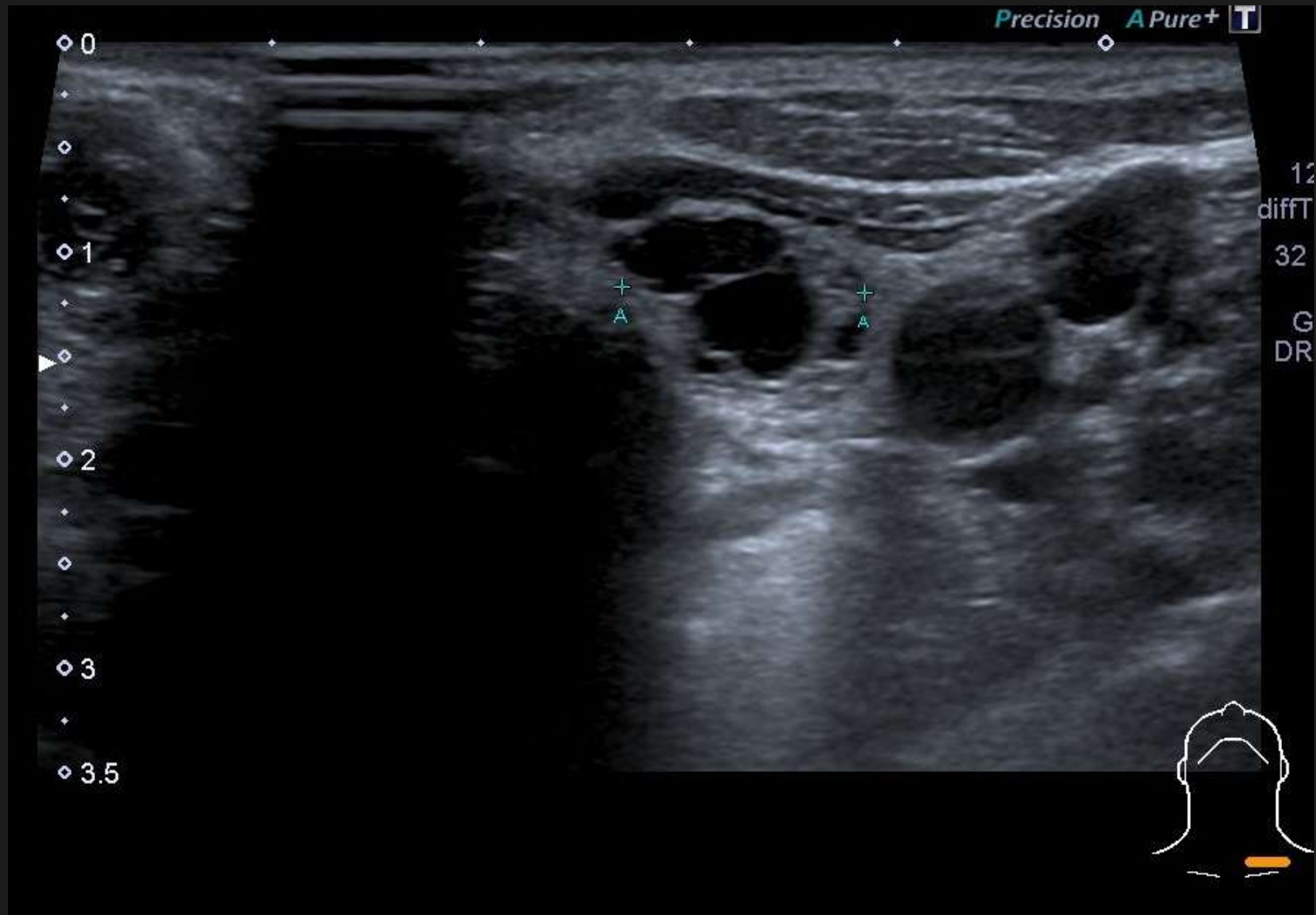
- Problem?
- Solution – Ultrasound & brain.
- Practice.

Case 1.

Precision A Pure+ T

12
diffT
32
G
DR

0
1
2
3
3.5



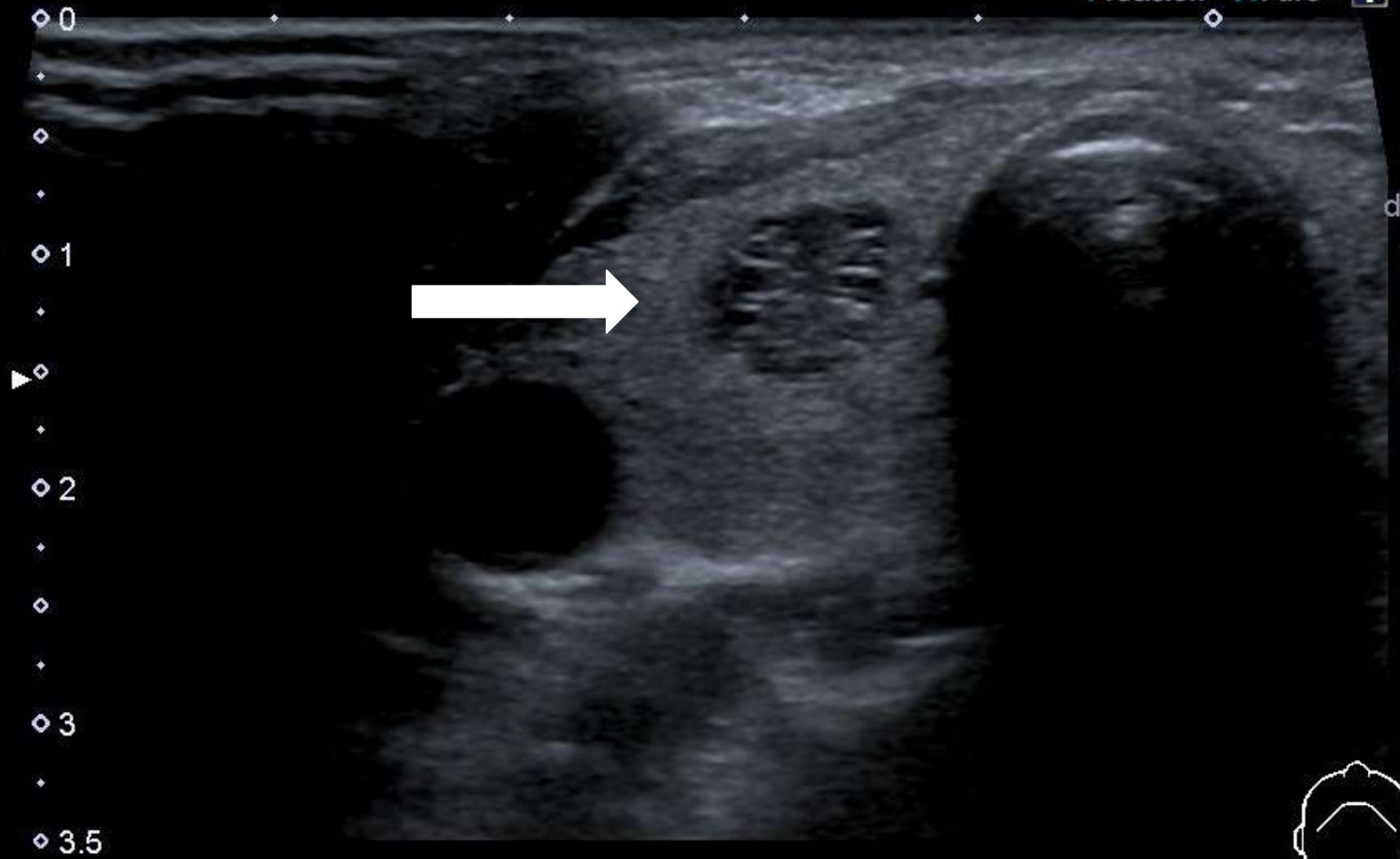
Precision A Pure+ T

0
1
2
3
3.5

A +
A +

12
diffT
32
G
DR

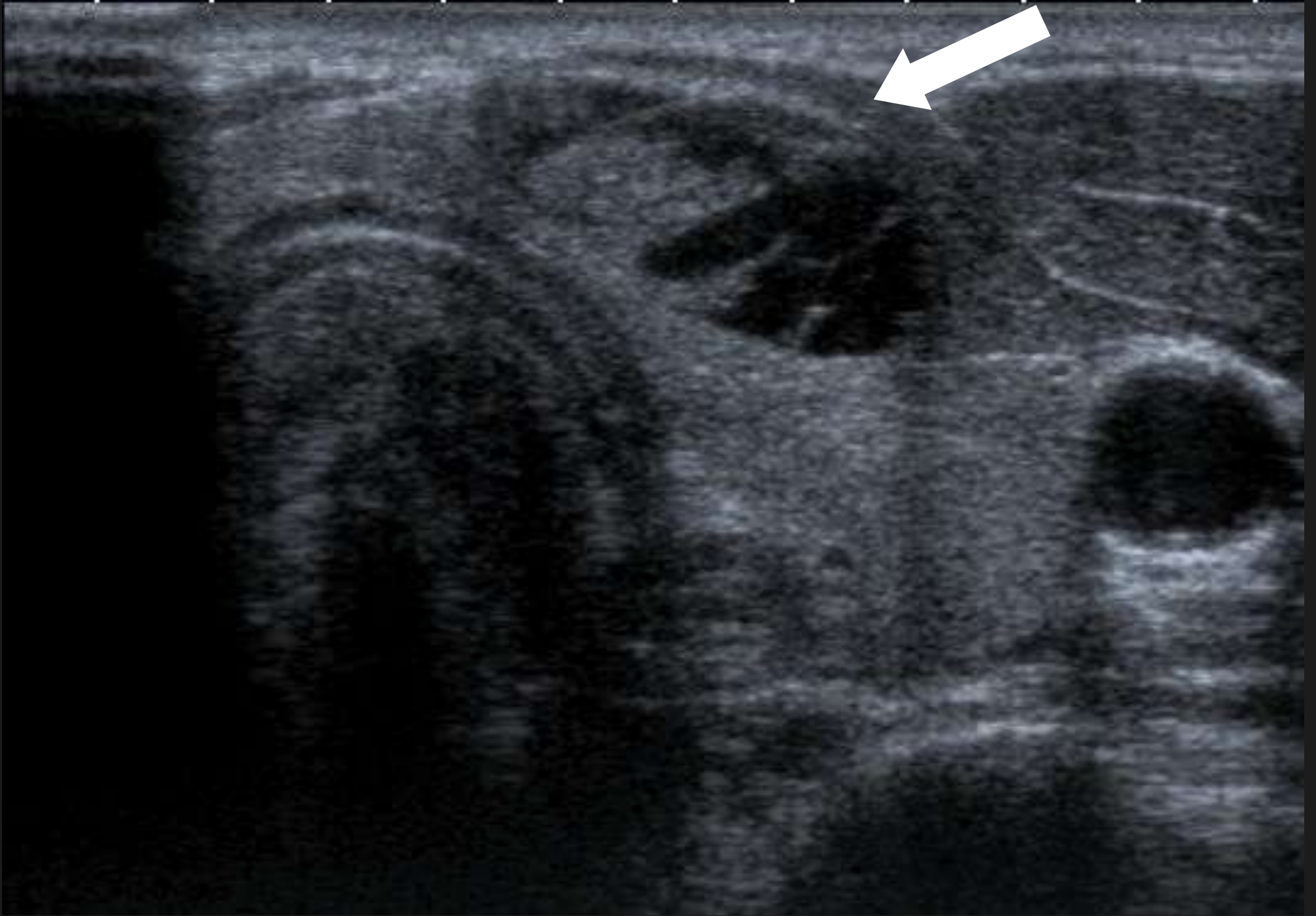




1
diff
32
C
DF



Case 2



TOSHIBA

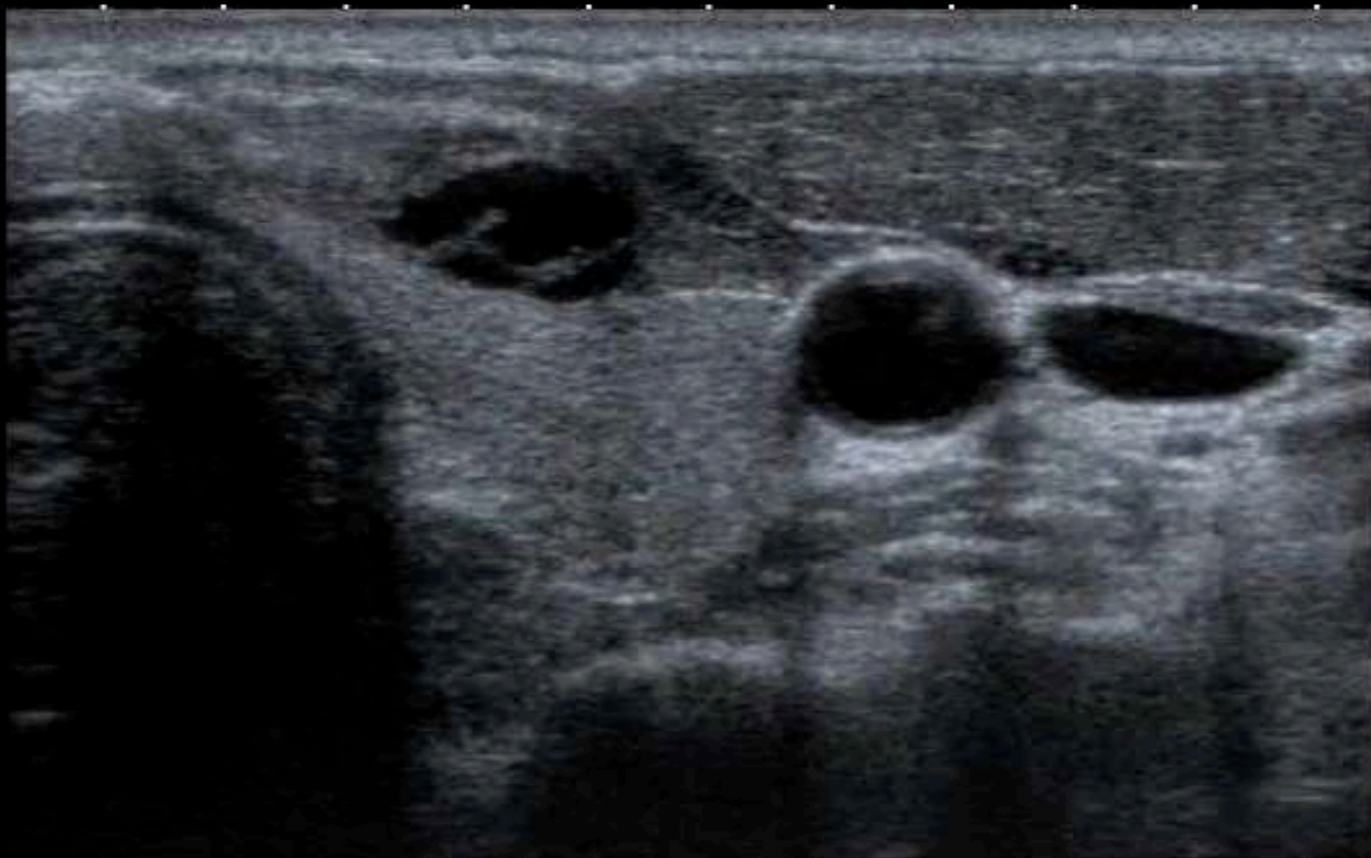T896236:DUGUID IAN 50 M
SINGLETON HOSPITAL - SS - THYROID 1

18/07/2006
11:26:06 AM

T
0
1
2
3
4

12L5
T9.0


33 fps



MI: 1.6
2DG
93
DR
70



HDD:58% Free



Case 3

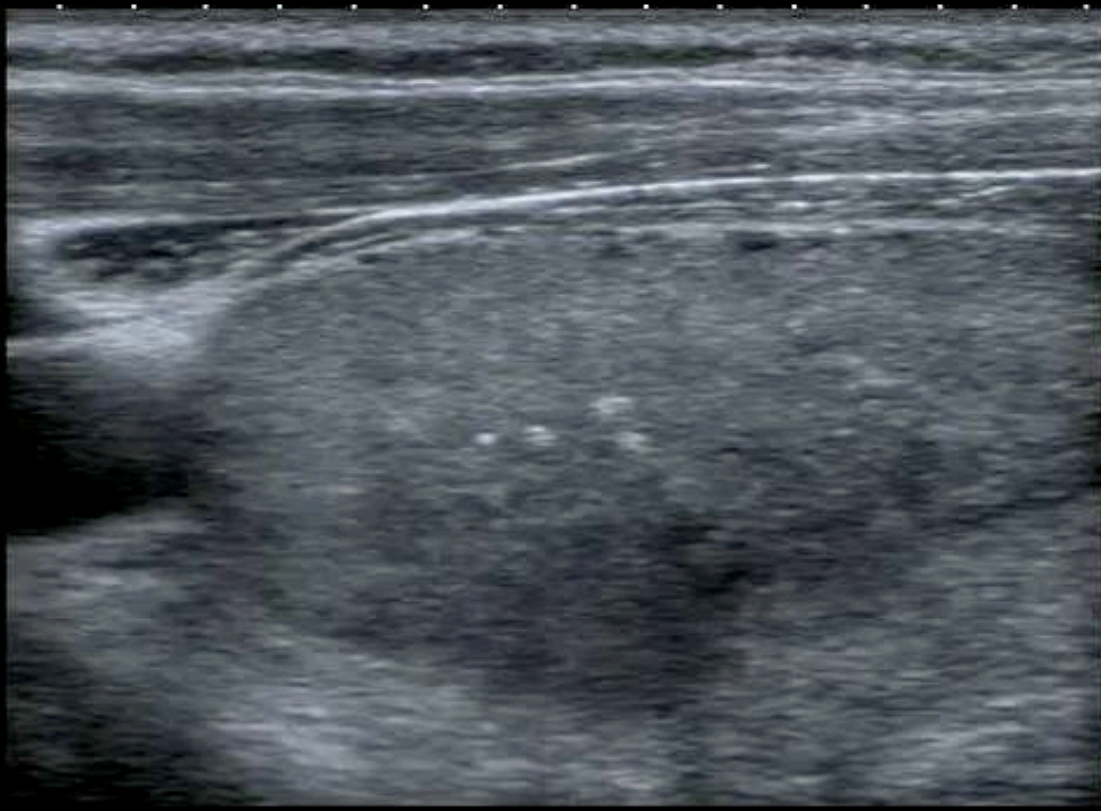
TOSHIBA

2251230:WESTOVER ANNE 54 O
YSTRADGYNLAIS - OPE - Thyroid 2

03/09/2008
11:28:32 AM



0 ◆
.
.
1 ◆▶
.
.
2 ◆
.
.
3 ◆



T

14L7
diffT13.0
25 fps

MI:1.4
2DG
80
DR
65

IP4

HDD:63% Free



TOSHIBA

2251230:WESTOVER ANNE 54 O

YSTRADGYNLAIS

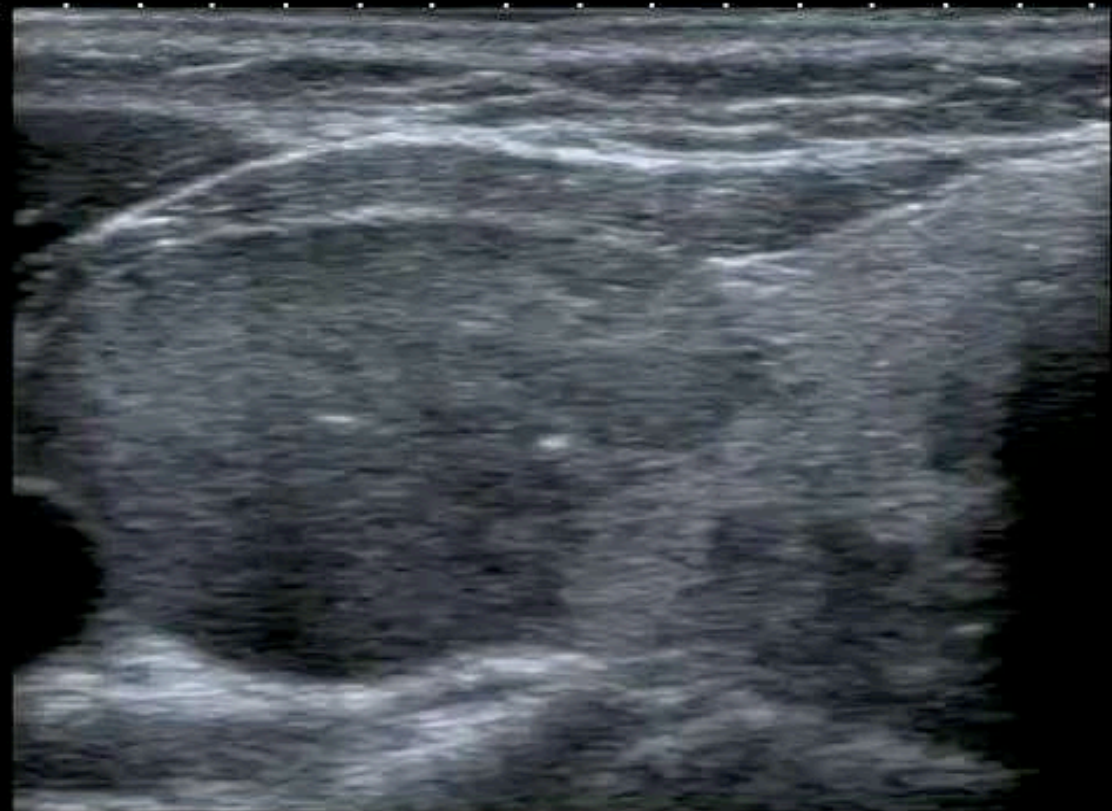
- OPE - Thyroid 2

03/09/2008

11:35:42 AM



0 ◆
.
.
1 ◆▶
.
.
2 ◆
.
.
3 ◆



T

MI: 1.4
2DG
80
DR
65

14L7
diffT13.0

25 fps

IP4

HDD: 63% Free



Thyroid cancer : overview.

- Engage the brain
- Overdiagnosis
- Signs
- U classification
- Needle?
- Manage the patient correctly.



© www.aberystwyth.org.uk

www.headandneckultrasound.co.uk